

Colorectal Polyps





Information and Surveillance Recommendations

Several types of colorectal polyps may be identified and removed during colonoscopy. When determining future surveillance intervals, consideration must be given to the adequacy of the bowel preparation of the previous procedure, family history, the presence of residual polyps, and the completeness of polyp removal. Clear communications between the endoscopist, patient and healthcare provider is critical to ensuring appropriate care.

Adenomas

Conventional adenomas (adenomatous polyps) are benign neoplasms with at least low grade dysplasia (LGD) that may progress to polyps with high grade dysplasia (HGD) or invasive carcinomas if not removed. Ongoing colonoscopic surveillance is indicated after polyp removal as these patients are at elevated risk.

Serrated adenomas are pre-malignant polyps. Serrated adenomas presenting with dysplasia are considered to be 'advanced' adenomas, a morphological indication that the polyps are undergoing malignant transformation. Sessile serrated adenomas/polyps (SSA/Ps) likely cause a significant percentage of colorectal cancers (CRC).

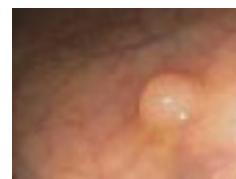ADENOMA TYPE	DESCRIPTION	COLONOSCOPY SURVEILLANCE INTERVAL
CONVENTIONAL ADENOMAS		
Tubular Adenomas 	<1.0 cm without HGD Lower risk for malignant transformation.	5-10 years
	≥1.0 cm or with HGD Higher risk for malignant transformation.	3 years
Villous and Tubulovillous Adenomas 	Higher risk for malignant transformation. Tubulovillous adenomas are a mixed type with an intermediate risk between villous and tubular adenomas.	3 years
SERRATED ADENOMAS		
Sessile Serrated Adenomas/Polyps (SSA/Ps) 	<1.0 cm without dysplasia Increased risk for malignant transformation. Typically a pale, sessile lesion that rests on the crest of the mucosal folds, predominantly found in the proximal colon. Includes unclassified serrated polyps and hyperplastic polyps proximal to splenic flexure.	5 years
	≥1.0 cm or with dysplasia Higher risk for malignant transformation.	3 years
Traditional Serrated Adenomas (TSAs) 	Higher risk for malignant transformation. Rare adenoma type that should be followed as per high-risk adenomas. Typically seen as a pedunculated lesion in the left colon. May have dysplasia (+/- HGD), with advanced TSAs at greater risk similar to HGD in conventional adenomas.	3 years
Serrated Polyposis Syndrome (SPS)	Increased risk for malignant transformation. Must meet at least one of: <ul style="list-style-type: none"> • ≥ 5 serrated polyps proximal to the sigmoid, with at least two ≥1.0cm. • Any number of serrated polyps proximal to the sigmoid and a 1st degree relative with serrated polyposis syndrome. • >20 serrated (includes hyperplastic polyps) polyps of any size throughout the colon. 	1 year
	First degree relatives of patients with SPS are reported as having increased lifetime risk of CRC. Recommendations for those affected is to commence colonoscopic surveillance at age 40 or 10 years earlier than the youngest age of diagnosis of SPS in the family (whichever comes first).	5 years

Adenoma features that increase risk of malignant transformation*

ADENOMA FEATURE	COLONOSCOPY SURVEILLANCE INTERVAL
Presence of HGD or villous components. Grade of dysplasia is a reflection of the degree of histological differentiation. Complete removal should be ensured, dysplasia noted at the resection margin may suggest incomplete excision.	3 years
Size ≥1.0cm	3 years
Quantity 3-10	3 years
Quantity >10**	1 year

*Adenomas are considered advanced adenomas in the presence of HGD, villous components, and ≥ cm in size. High risk adenomas (HRAs) include advanced adenomas and/or individuals with 3 or more adenomas.

**Consider referral for genetic testing.



Hyperplastic Polyps

True hyperplastic polyps are a type of serrated polyp that have no malignant potential. Small hyperplastic polyps (<1.0cm) found in the rectum and sigmoid require no specific follow up. However, more proximal hyperplastic polyps are not easily distinguished from sessile serrated adenomas. If in doubt colonoscopic surveillance should follow accordingly. Consultation with the pathologist may be necessary.

Family history and surveillance/screening intervals

FAMILY HISTORY	COLONOSCOPY SURVEILLANCE INTERVAL
Two or more 1 st degree relatives diagnosed with CRC at any age.	Every 5 years beginning at age 40 or 10 years earlier than the youngest relatives diagnosis.
One 1 st degree relative diagnosed with CRC at any age.	Every 5 to 10 years beginning at age 40 or 10 years earlier than the youngest relatives diagnosis.
One or more 1 st degree relatives diagnosed with documented advanced adenomas (≥1 cm in size, or with high-grade dysplasia, or villous and tubulovillous lesions) at any age.	Every 5 to 10 years or FOBT every 1 to 2 years beginning at age 40 or 10 years earlier than the youngest relatives diagnosis.

Large sessile polyp (>2.0cm)

Patients with colonoscopic excision of large sessile polyps (>2.0cm) should undergo follow-up colonoscopy in 3-6 months to be sure the resection was complete. If residual polyp is present, it should be resected and another colonoscopy completed in 3-6 months. If complete resection is not possible after 2 or 3 examinations, the patient should be referred for surgical therapy. Residual lesions should be tattooed to assist with identification at repeat colonoscopy or surgery.

Other Polyps

Inflammatory polyps, mucosal prolapse, prominent mucosal folds and polyps composed of lymphoid follicles do not require colonoscopic follow-up. In cases where hamartomatous polyps are encountered, additional investigation may be required to determine whether syndromes such as Peutz-Jeghers are present.

Malignant Polyps

Completeness of excision must be assured in malignant (invasive adenocarcinoma) polyps. Need for surgical management should be considered taking into account the presence/absence of poorly differentiated adenocarcinoma, presence of agiolymphatic invasion, and the distance of invasive adenocarcinoma from margin of resection (positive margins are considered <1.0 mm).

Adenocarcinoma

Patients with invasive adenocarcinoma must have appropriate workup and surgical consultation arranged.

ColonCheck is the provincial colorectal cancer screening program operated by CancerCare Manitoba. ColonCheck distributes FOBT kits to eligible Manitobans 50 to 74 years of age, manages test results, and arranges follow-up colonoscopy for individuals with positive test results.

- In cases where the follow-up colonoscopy is negative (including small distal hyperplastic polyps), ColonCheck will automatically recall the patient in 5 years for routine CRC screening with FOBT.
- In cases where the follow-up colonoscopy is positive (adenomas are detected), ColonCheck will not recall the patient as they are no longer eligible for routine CRC screening with FOBT. Future colonoscopic surveillance must be arranged by the healthcare provider.

For more information on colorectal cancer screening guidelines and full reference listing, visit www.cancercare.mb.ca/screening

Thank you to the Colon Screening Program, BC Cancer Agency for their permission to reprint from the Colorectal Polyp Information Sheet for Health Care Providers, November 2013. Images reprinted with permission from Colorectal Cancer Screening and Surveillance, January 15, 2015, Vol 91, No. 2. American Family Physician Copyright © 2015 American Academy of Family Physicians. All Rights Reserved.

Get checked Manitoba.

Cancer screening saves lives.

BreastCheck ✓ CervixCheck ✓ ColonCheck ✓

1-855-95-CHECK

cancercare.mb.ca/screening