

Chapter 8: External & Speculum Exam

On completion of this section, the learner will be able to:

1. Describe how to perform a person-centered physical examination of the external genitalia.
2. Understand the function of and use of metal and disposable speculums.
3. Describe how to perform a person-centered speculum examination.
4. Identify requirements for follow-up.

Learning Objectives

Exam Equipment

You will need the following supplies:

- Vaginal speculum of appropriate size
- Portable or wall light or an attachable speculum light source
- Latex free gloves

Ensure a new plastic speculum is used for each exam. If metal speculums are still in use in your facility, you must ensure that appropriate infection control procedures are followed for cleaning and maintaining these instruments.^{1 2 3}

Important Information

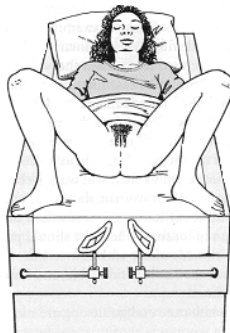Preparing the Client⁴

- Introduce yourself to the client before they change into a gown.
- Obtain a relevant health history as explained in Chapter 7: Health History.
- Explain the steps to and the reason for performing an external genital exam, speculum exam and Pap test.
- Obtain verbal consent to proceed with the external examination, speculum exam and Pap test procedures.
- Provide the client with instructions for changing:
 - Remove clothing from the waist down.
 - Put on gown with ties facing the back and place the drape over your legs.
 - Remove a tampon, if wearing one.
 - To minimize discomfort while inserting the speculum and to allow for easier palpation, have the client void prior to the procedure.

- Either leave the room while the client undresses or pull a curtain within the room to ensure maximum privacy
- If possible, raise the head of the bed to a 40-degree angle or more. Once the client has moved to the edge of the bed they won't be sitting up this high. The benefits of raising the head include:
 - Eye contact can be maintained throughout the procedure to observe any grimacing or signs of discomfort.
 - The position naturally relaxes the abdominal and pelvic muscles.
 - The client can see the foot supports in order to place their feet.
 - This position allows the client to feel more empowered and part of the exam.
- Run a drape from the client's abdomen to their knees. This can add to their sense of privacy especially if there is a chaperone present.
- Assist the client into the lithotomy position so that their body is supine and her buttocks extends over the end of the bed by approximately one inch. Encourage the client to relax their leg muscles, letting their knees part to start the exam.

In the M-Shaped position the client:

- lies on their back
- knees bent and apart
- feet resting on the examination table close to their buttocks



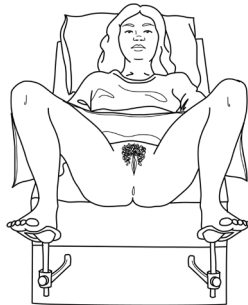
"The speculum must be inserted with the handle up. If the client feels their legs are not completely stable on the examination table, an assistant may support their feet or knees. The M-Shaped position does not require the use of stirrups."²

The M-shaped position

Source: Seidel, H.M., Ball, J.W., Dains, J.E., & Benedict, G.W. (1987). Mosby's Guide to Physical Examination. Reprinted with permission from Elsevier.

In the lithotomy position the client:

- lies on their back
- buttocks extends over the end of the bed by approximately one inch
- knees bent and apart
- feet resting in the foot stirrups



The HCP can discuss the use of alternate positions such as foot supports for lithotomy position, M-shaped or knee chest positions as explained below.

The Lithotomy Position

Source : Seidel, H.M., Ball, J.W., Dains, J.E., & Benedict, G.W. (1987). Mosby's Guide to Physical Examination. Reprinted with permission from Elsevier.

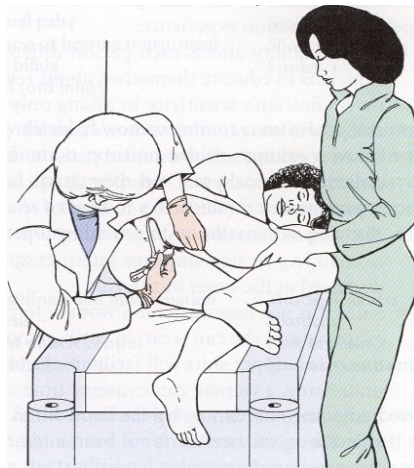Knee-chest (side-lying) Position

In the Knee-Chest (Side-Lying) Position the client:

- lies on their side with both knees bent, top leg is brought closer to their chest, OR
- lies with their bottom leg straightened while the top leg is still bent closer to their chest

“The speculum can be inserted with the handle pointed in the direction of the abdomen or back. Because the client is lying on her side, the HCP should be sure to angle the speculum toward the small of the client’s back and not straight up toward their head.”⁴

“The assistant may provide support for the client while they are on the examination table or help them straighten their bottom leg if they prefer the variation of this position. If the client cannot spread their legs, the assistant may help them elevate one leg. The knee-chest position does not require the use of stirrups. It is particularly good for a client who feels most comfortable and balanced lying on her side.”² This position is helpful for elderly or physically disabled clients who have less range of motion. Note: Most clinic rooms have the bed against the wall so the HCP should approach the client from the right side and the client would be lying on the left side.



Source : Seidel, H.M., Ball, J.W., Dains, J.E., & Benedict, G.W. (1987). Mosby's Guide to Physical Examination. Reprinted with permission from Elsevier.

- Sit on a stool at the foot of the examining table.
- Explain each step of the examination before it is done. Ensure the client understands that they have a choice about how much information is shared with them about the procedures for the examination. While some clients wish to know about each step of the exam, others would prefer to hear very little detail. Get a sense from the client what their preference is. Ask them to tell you if there is any pain or discomfort during the procedure.

The external examination is a part of the Well Woman's examination. However, this learning module is designed to give you detailed information to become competent in performing Pap tests. Check with your facility or regional policy to determine if an external exam is part of the care you will provide, and if so, what training will be provided to you as the learner. The external examination may be part of your preceptorship but for the purpose of this module, it is not outlined as a learning objective.

Important Information

External Examination⁵

Follow these steps:

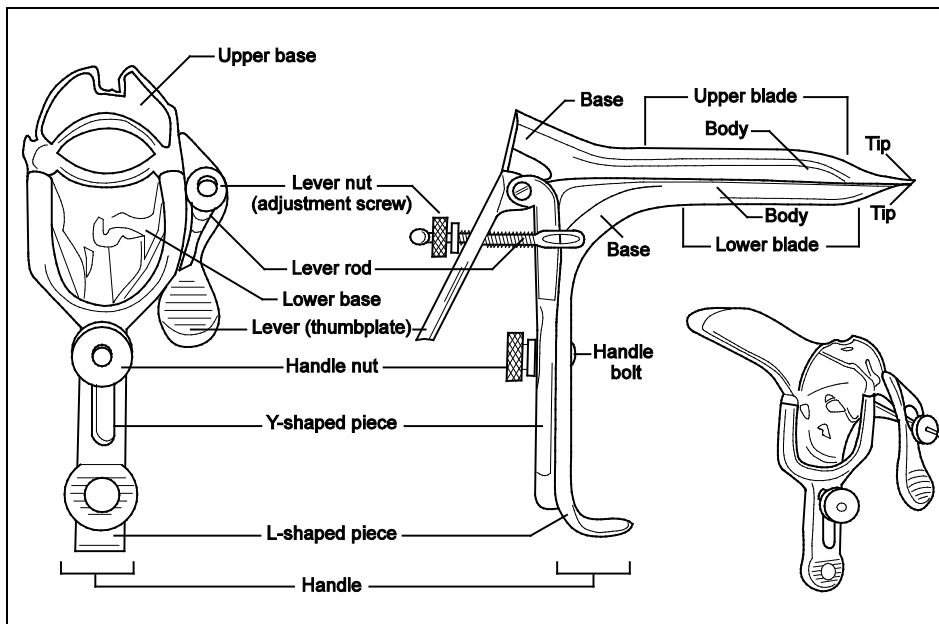
- Wash hands and glove.
- Warn the client prior to palpating the inner thigh and labia for examination. The following phrases are encouraged: "You will feel the back of my hand on your thigh," or "now you will feel my hand on your genitals," or "you will feel me start the exam now." Examine each area for any visual abnormalities.
- Separate the labia with the fingers of the non-dominant gloved hand. Doing this allows visualization of the tissue and creates an opening for speculum insertion.

Speculum Exam Procedure⁶

It is essential that you become thoroughly familiar with how the speculum operates before you begin the examination so that you do not inadvertently hurt the client. Become familiar with the operation of the metal speculum and the disposable plastic speculum. The mechanical action of each is somewhat different. Some plastic specula typically make a loud click when locked or released. It is therefore important to forewarn the client about this click and avoid surprise and unnecessary anxiety.

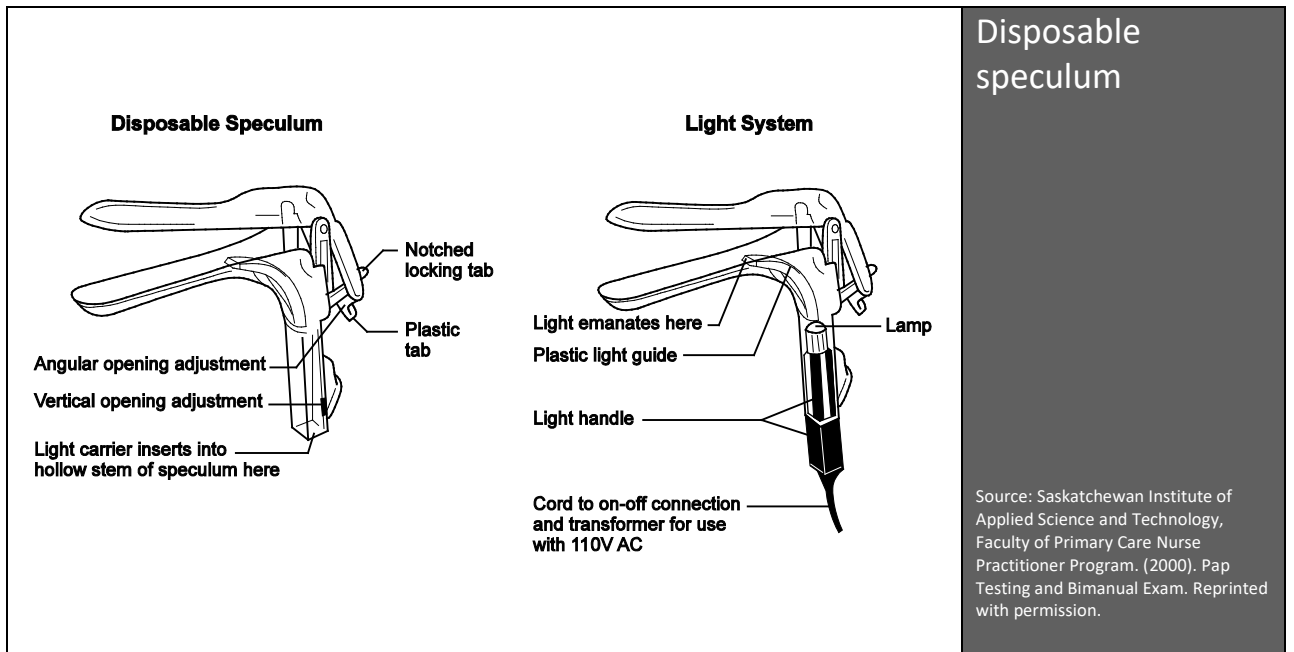
If metal speculums are the standard practice at your facility, you must ensure that the appropriate infection and control procedures are followed for cleaning and maintenance of these instruments.

Important Information



Metal speculum

From Faculty of Primary Care Nurse Practitioner Program, Saskatchewan Institute of Applied Science and Technology (2000). Pap Testing and Bimanual Exam, p. 25. Reprinted with permission.



<p>Locate plastic and metal speculums at your facility. Handle and review the parts of the speculums as per the above diagrams to understand how they function.</p>	<p style="font-size: 1.2em; margin-bottom: 0;">Important Information</p>
---	---

After taking the client’s health history and examining the external genitalia, you will have an idea of the appropriate type and size of speculum needed. A smaller and narrower speculum may need to be used with nulliparous clients, clients who have undergone FGC, clients who have vaginismus, clients whose vaginal introitus has contracted post menopausally, or clients who have never had sexual intercourse.

Now begin the speculum exam:

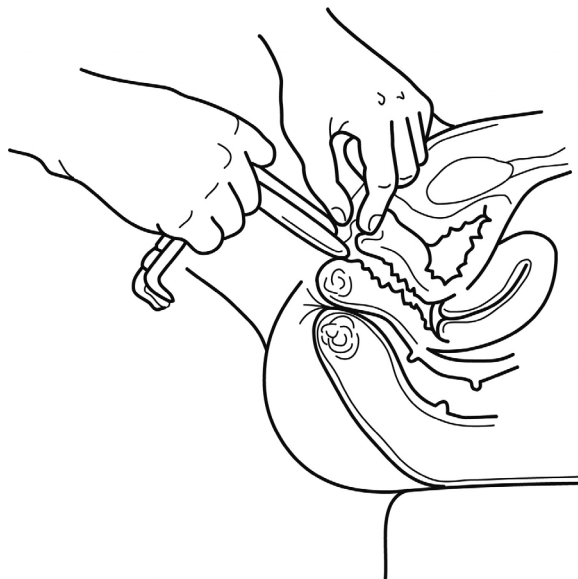
- Select the proper sized speculum that best matches the anatomy of the client.
- If you are using a metal speculum:
 - ensure the setscrew on the long handle (holding the two blades of the speculum together) is kept tightened
 - loosen the setscrew that holds the thumbscrew in place
- If you are using a plastic speculum:
 - ensure that it is in its most closed position
- Warm the speculum by rinsing it in warm (not hot) water, holding it in your gloved hand or under the lamp for a few minutes, or by having speculums on a warm heating pad (test temperature against wrist before inserting). A cold speculum increases muscle tenseness. Inform the client that this warming procedure is done for their comfort and that the speculum has previously been disinfected.
- Use a water-soluble vaginal lubricant on the outer inferior blade of the speculum.

As a client ages their vaginal walls atrophy and therefore are drier than a younger client. Special attention to the client's comfort should be a priority.

**Important
Information**

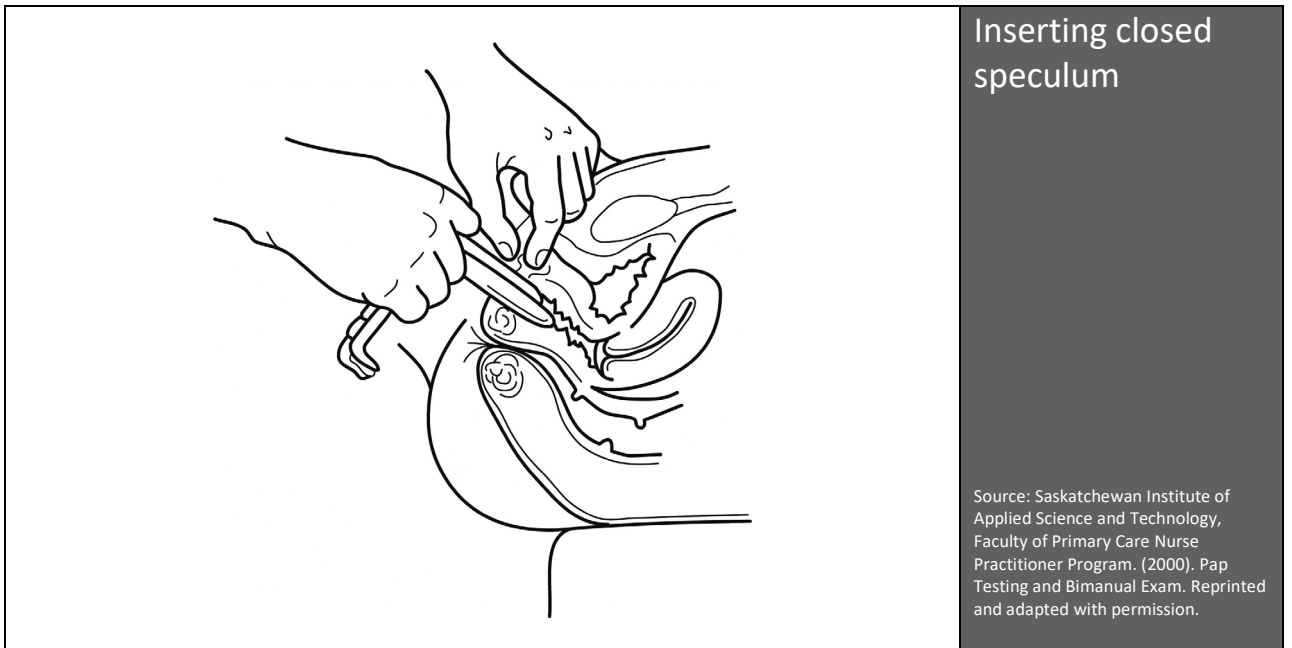
- Grasp the speculum with your dominant hand. The index and middle fingers should surround the blades and the thumb should rest against the back of the thumb lever to keep the tips of the blades closed.
- Tell the client that they are going to feel you examine them. With the index and middle fingers of the other hand, open and push downward on the vaginal orifice. This makes the speculum exam more comfortable.

- Place the blade tips against the lower (posterior) wall of the vagina to avoid contact with the urethra. Some HCPs insert the speculum blades at an oblique angle, while others prefer horizontal. In either case, avoid touching the clitoris, catching pubic hair or pinching labial skin. Slowly insert the speculum maintaining gentle downward (toward posterior wall of vagina) pressure to avoid trauma to the urethra and vaginal walls. Firmly “sweep” away any hair or tissue that may have been pulled into the vagina.
- Insert the closed speculum at the anatomic angle of the vagina (45° angle downward toward the small of the woman’s back) while maintaining downward pressure until resistance is met and then pull back slightly.



Preparing to insert closed speculum

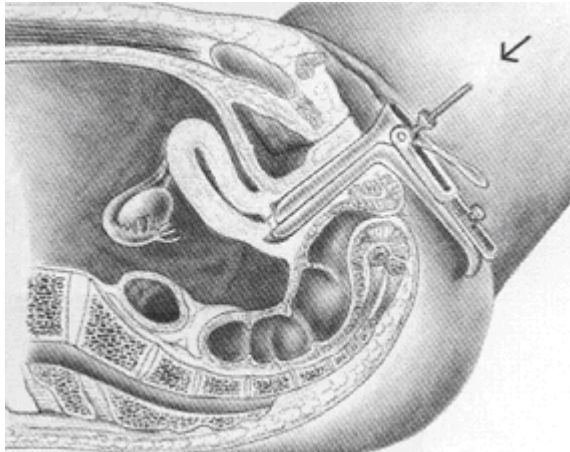
Source: Saskatchewan Institute of Applied Science and Technology, Faculty of Primary Care Nurse Practitioner Program. (2000). Pap Testing and Bimanual Exam. Reprinted and adapted with permission.



Inserting closed speculum

Source: Saskatchewan Institute of Applied Science and Technology, Faculty of Primary Care Nurse Practitioner Program. (2000). Pap Testing and Bimanual Exam. Reprinted and adapted with permission.

- Insert the speculum up to the base of the cervix (the posterior fornix area) and then rotate it horizontally. Apply gentle pressure on the speculum against the perineum to help place the blade tips in the posterior fornix.
- Remove the hand that has separated the labia.

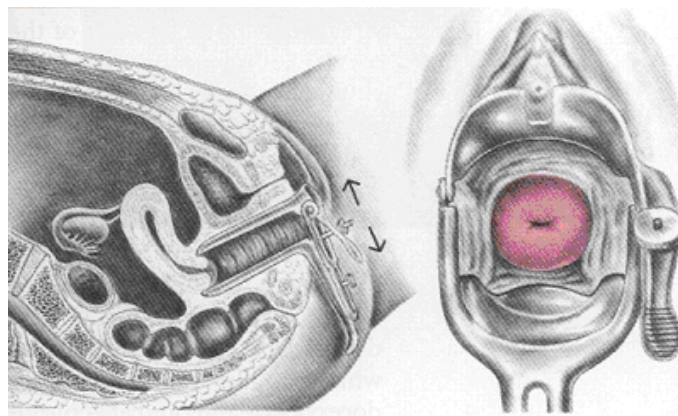


Speculum fully inserted

Source: Seidel, H.M., Ball, J.W., Dains, J.E., & Benedict, G.W. (1987). Mosby's Guide to Physical Examination. Reprinted with permission from Elsevier.

- Maintaining downward pressure of the speculum, open it by pressing on the thumb piece. Open the speculum as little as possible to see the cervix. Greater vaginal distension is unnecessary, and painful.
- Move the speculum blades slowly upward until the cervix comes into view. Adjust the light source. Note: if the speculum is directed posteriorly on insertion, it is easier to find the cervix and avoid a lot of unnecessary up and down movement of the speculum, which is uncomfortable for the client.
- If this attempt is unsuccessful and the cervix cannot be visualized, close the blade tips and withdraw the speculum slightly, then reinsert more deeply and posteriorly, with the base of the lower blade actually compressing the perineum. Then slowly move the blades upward again. Evaluate vaginal roof (wrinkled) and floor (smooth) and look for the position of the cervix. Determine direction you wish the blades to go. If this is still unsuccessful, remove the speculum, perform bimanual to locate the cervix using vaginal lubricant, and then reinsert the speculum.
- If you are using a metal speculum:
 - once the cervix is central and clearly in view, tighten the lever nut to lock the blade tips in the open position

- If you are using a plastic speculum:
 - open the blade of the speculum until it is positioned such that you may visualize the cervix. Let the patient know they will hear 1 – 2 clicks.



Speculum open to view cervix

Source: Seidel, H.M., Ball, J.W., Dains, J.E., & Benedict, G.W. (1987). Mosby's Guide to Physical Examination. Reprinted with permission from Elsevier.

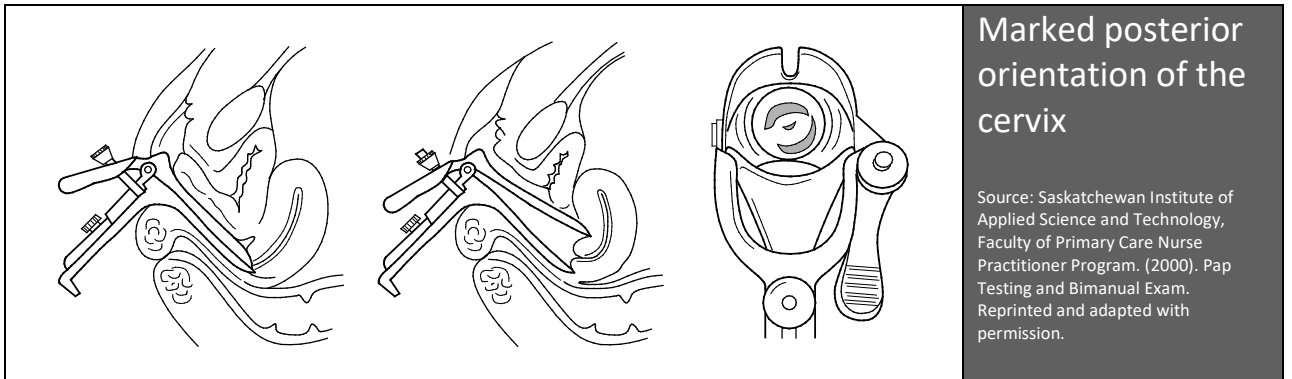
In most clients, the cervix has a posterior orientation that slightly obscures the cervix due to the vaginal walls. The cervix can be further obscured through a retroverted uterus, marked posterior orientation of the cervix or laxity of the vaginal walls. The entire cervix should be visible in order to obtain the Pap test.

Clients with Retroverted Uterus

A cervix that is pointing anteriorly indicates a retroverted uterus. The speculum has to be much further forward and the HCP may have to invert speculum to see the cervix.

Clients with Posterior Orientation of the Cervix

Insert the speculum more deeply and posteriorly through compression of the perineal tissue. The blade tips will slip under the cervix into the posterior fornix.



Clients with Laxity of the Vaginal Walls

An inability to visualize the cervix due to laxity of vaginal walls may occur in some clients (e.g. obese and multiparous clients). The blade base, as well as the tips have to be opened when using a metal speculum. Loosening the handle nut in the metal speculum and pushing the Y-shaped piece upwards accomplishes this. Alternatively, a large metal speculum can also be used. For the plastic speculum, a larger size may be needed. Placing a condom over the speculum with the tip removed also assists in visualizing the cervix by supporting the vaginal walls.

- Inspect the cervix.

Depending of your scope of practice, all abnormal findings need to be investigated appropriately or referred to a specialist. A Pap test may provide a false negative result.

Important Information

Assess the Following Features of the Cervix:

Colour

Pink, with the colour evenly distributed. A bluish colour indicates increased vascularity that may be a sign of pregnancy. Symmetric circumscribed erythema around the os is a normal finding that indicates exposed columnar epithelium from the cervical canal.

Check for:

- reddened areas: beginning HCPs should consider any reddened areas as an abnormal finding, especially if patchy or if the borders are irregular
- pale cervix: may indicate anemia or menopause

Position

Correlates with the position of the uterus. A cervix that is pointing:

- anteriorly indicates a retroverted uterus
- posteriorly indicates an anteverted uterus
- horizontally indicates a uterus in midposition

The cervix will be more posterior with the anteverted or anteflexed uterus and more anterior with the retroverted or retroflexed uterus. The cervix projects about 1 to 3 cm into the vagina.

Check for:

- deviation to the right or left may indicate a pelvic mass, uterine adhesions, or pregnancy
- projection greater than 3 cm may indicate a pelvic or uterine mass

Size

The diameter ranges from 2 to 3 cm. However, clients who have had multiple pregnancies may have larger diameters.

Check for:

- enlarged cervix may indicate cervical infection

Shape of the Os

The os of the nulliparous client is small, round, or oval. The os of a multiparous client is usually a horizontal slit or may be irregular and stellate. Trauma from induced abortion or difficult removal of an intrauterine device may change the shape of the os to a slit.

Note if the os is:

- | | |
|------------------------------|--------------------------------|
| • small and round | • bilateral transverse slit |
| • horizontal irregular slit | • stellate |
| • unilateral transverse slit | • cervical eversion is present |

Surface

The surface of the cervix should be smooth. Some squamocolumnar epithelium of the cervical canal may be visible as a symmetric reddened area around the os. Nabothian cysts may be observed as small, white or yellow, raised, round areas on the cervix and are considered to be a normal finding.

Check for:

- friable tissue (soft, eroded, may be bleeding), red patchy areas, abnormal bleeding, inflammation, pebbly growths, granular areas, and white patches that could indicate infection, or carcinoma. Refer for colposcopy or reassessment by another HCP as per your facility or region policy.
- nabothian cyst: becomes swollen with fluid and distorts the shape of the cervix, giving it an irregular appearance
- polyps: refer to HCP as per your facility or region policy
- a poorly visualized os appearing in inflamed tissue

Secretions

Determine whether the discharge comes from the cervix itself, or whether it is vaginal in origin and has been deposited in the cervix. Normal discharge is odorless, may be creamy or white, may be thick, thin, or stringy, and is often heavier at midcycle or immediately before menstruation.

Check for:

- abnormal vaginal discharge (refer to Chapter 6: Summary Chart of Discharges, Infections, Ulcers and Lesions)

If there is a suspicion of malignancy (inflammation of the cervix, fungating lesion, ulcerative lesion, abnormal bleeding from cervix) or if the woman has a history of abnormal bleeding (post-coital, intermenstrual, postmenopausal, or heavy irregular bleeding), depending on your scope of practice you should investigate appropriately or refer to a specialist.

Important Information

- Perform Pap test (see Chapter 9).

-
- If you are using a metal speculum:
 - loosen the thumbscrew but continue to hold the speculum blades open
 - If you are using a plastic speculum:
 - unlock the notch locking tab while continuing to hold the speculum blades open
 - Slowly withdraw the speculum, rotating it as you go to fully inspect the vaginal wall. The colour should be a similar pink colour as the cervix, or a little lighter. Clients with adequate estrogen levels have pink, moist, smooth or rugose and homogenous vaginal walls. Normal secretions that may be present are usually thin, clear or cloudy, and odorless.

Check for:

- inflammation
- lesions
- swelling
- cracks
- abnormal discharge
- abnormal colour
- presence or absence of rugae
- reddened patches, lesions, or pallor indicates a local or systemic pathologic condition
- secretions that are profuse (thick, curdy, or frothy, appear gray, green, or yellow, and may have a foul odor) indicate infection
- Close the blades when the end of the blades nears the vaginal opening, making sure that no vaginal mucosa, skin, or hair remains between the closed blades. Maintain downward pressure of the speculum to avoid trauma to the urethra. Note the odor of any vaginal discharge that has pooled.
- Place the used metal speculum in the recommended medium for infection control and cleaning, or dispose of disposable speculum.
- Discard your gloves and wash hands.

-
- Inform the client that the procedure is over and that they can move into a seated position. Be sure to inform the client that they may contact CervixCheck or her HCP for their results. This may also be an opportunity to educate the client about harm reduction and cervical screening guidelines. Inform the client that you will leave for a minute while they get dressed and that you will return to discuss treatment and/or education.
 - Offer a tissue to the client and tell them that spotting may occur and that this is normal. If appropriate, offer her a panty liner.

Special Considerations

Clients with Hysterectomy⁷

For clients who may have had a hysterectomy, screening of the vaginal vault may still be necessary. HCPs should confirm the pathological history in order to determine how to proceed and/or refer to their facility or regional policy.

Screening of the vaginal vault with a broom or spatula is not necessary if the client meets all of the following conditions:

- they have had a total hysterectomy (as opposed to a subtotal hysterectomy)
- the hysterectomy was performed for a benign disease (pathology negative for high-grade dysplasia), and
- they have had no previous high-grade Pap test result.

If Pap test results or hysterectomy pathology is unavailable, continue screening until two negative vaginal vault tests occur.

Examine the external genitalia for atrophy, skin changes, decreased resilience, and discharge. On speculum examination, the cervix will be absent. Assess the walls, mucosa, and secretions as you ordinarily would. The vaginal canal of a client who has had a total hysterectomy might show the same changes as those that occur with menopause (such as decrease in rugae and secretions), especially if the woman is not receiving hormone replacement therapy. Examine for a cystocele or rectocele. Stress incontinence may be a problem, so observe for this when having the client bear down.

Older Women⁸

The examination procedure for older clients (ages 55 – 69) is the same as that for the client of childbearing age, with a few modifications for comfort. The older client may require:

- more time and assistance to assume the lithotomy position
- assistance from another individual to help hold their legs, since they may tire easily when the hip joints remain in abduction for an extended period
- head and chest elevated during examination if they have orthopnea
- use of a smaller speculum depending on the degree of introital constriction that occurs with aging

Note that, in comparison to a younger adult, the older client's:

- labia appear flatter and smaller, corresponding with the degree of loss of subcutaneous fat elsewhere on the body
- skin is drier and shinier
- pubic hair is gray and may be sparse
- clitoris is smaller
- urinary meatus may appear as an irregular opening or slit. It may be located more posteriorly, very near, or within the vaginal introitus as a result of relaxed perineal musculature.
- vaginal introitus may be constricted and admit only one finger. In some multiparous older clients the introitus may gape with the vaginal walls rolling toward the opening.
- vagina is narrower and shorter, and you will see and feel the absence of rugation
- cervix is smaller and paler, and the surrounding fornices may be smaller or absent. The cervix may seem less mobile if it protrudes less far into the vaginal canal. The os may be smaller, but, should still be palpable.
- pelvic musculature relaxes, so remember to look particularly for stress incontinence and prolapse of the vaginal walls or uterus

As with younger clients, you may note signs of inflammation (older clients are particularly susceptible to atrophic vaginitis), infection, trauma, tenderness, growth, masses, nodules, enlargement, irregularity, and changes in consistency. Any concerns should be referred.

	Recommended Reading
--	---------------------

Health Canada. (1998). *Canada communicable disease report: Cleaning, disinfecting and sterilizing patient care equipment*. Ottawa: Ontario.

Canadian Public Health Association. (2021). [Trauma-informed physical examinations and STIBBI testing: A guide for service providers](#). Ottawa: Ontario.

1. Describe the features and functioning of both the metal and disposable speculums.
2. What steps do you follow to properly insert the speculum?
3. What do you examine for the internal genital exam?
4. How might an older client's normal external and internal genitalia present in comparison to a younger adult?

Chapter 8 Self-Test

References

¹ Health Canada. (1998). Canada communicable disease report: Cleaning, disinfecting and sterilizing patient care equipment. Ottawa: Ontario.

² Provincial Infectious Diseases Advisory Committee. (2006). Best practices for cleaning, disinfection and sterilization in all health care settings. Toronto: Canada.

³ Centres for Disease Control and Prevention. (2008). Guideline for disinfection and sterilization in healthcare facilities. Chapel Hill: North Carolina.

⁴ This section is adapted from: a) Faculty of Primary Care Nurse Practitioner Program, Saskatchewan Institute of Applied Science and Technology (2000) & and Calgary Health Region (2001). Adapted with permission. And b) University of Manitoba, Clinical Teaching Assistant Post-Notes, (2013). Adapted with permission.

⁵ This section is adapted from Faculty of Primary Care Nurse Practitioner Program, Saskatchewan Institute of Applied Science and Technology (2000) & and Calgary Health Region (2001) A

⁶ This section is adapted from Faculty of Primary Care Nurse Practitioner Program, Saskatchewan Institute of Applied Science and Technology (2000) & and Calgary Health Region (2001) A & Cervical Screening Initiatives Program of Newfoundland and Labrador (2001).

⁷ Manitoba Cervical Cancer Screening Program. (2002). Pap smears: A resources guide for Manitoba health professionals. Manitoba: CancerCare Manitoba

⁸ Cervical Screening Initiatives Program of Newfoundland and Labrador. (2001). Papanicolaou smear: A clinic manual. Newfoundland: Canada.